

## **An investigation into factors contributing to mortality of young terns at a managed colony**

**Natassia Bacco-Mannina<sup>1\*</sup>, Heidi Acampora<sup>1</sup>, Ian O'Connor<sup>1</sup>, Stephen Newton<sup>2</sup> and Katie O'Dwyer<sup>1</sup>**

<sup>1</sup> Marine and Freshwater Research Centre, Atlantic Technological University, Old Dublin Road, Galway, H91 T8NW, Ireland;

<sup>2</sup> BirdWatch Ireland, Unit 20, Block D, Bullford Business Campus, Kilcoole, Co. Wicklow, A63 RW83, Ireland.

\* Corresponding author: [nbacco2000@gmail.com](mailto:nbacco2000@gmail.com)

## Abstract

Terns are a highly migratory group of seabirds that are found worldwide. In Ireland, there are five species of commonly breeding tern: Little Tern *Sternula albifrons*, Roseate Tern *Sterna dougallii*, Arctic Tern *S. paradisaea*, Common Tern *S. hirundo* and Sandwich Tern *S. sandvicensis*. Prior work has demonstrated that whilst many Irish tern species, including Common and Roseate Terns, are increasing in abundance, the productivity of these species can be low. Multiple factors may influence the ability of adult terns to successfully raise chicks, including food availability, provisioning rates, colony density, dependence effects, and/or disease. Here, we investigated factors contributing to the mortality of young terns from Rockabill Island in the Republic of Ireland, which supports the largest breeding population of Roseate Terns in Europe. To better understand the factors contributing to the deaths of young birds, we analysed the macroscopic and microscopic characteristics of necropsies of 60 young Common, Arctic and Roseate Terns. Of the carcasses that we examined, 41 showed congested blood circulation in the lungs and head simultaneously, and of the remaining 19 birds, only five presented a clear cause of death. Here, we outline descriptions of these carcasses in addition to recommendations of further investigations that might help to confirm the causal factors leading to young tern mortality.

## Introduction

Their marine specialisation, predatory roles and long lifespans mean that seabirds, including terns, are sensitive to changes in the marine environment (Dunn 2019) and are considered marine sentinels (Thibault *et al.* 2019). Changes in seabird population health and breeding success may therefore denote negative impacts deriving from pollution, food availability, or shifts in climate patterns (Furness & Camphuysen 1997). Seabirds are often directly exposed to anthropogenic impacts in the marine environment, including chemical substances (Pacyna *et al.* 2019), overfishing (Dias *et al.* 2019) and plastic pollution (Cartraud *et al.* 2019). Seabirds become contaminated via their diets, due to their predatory roles (Cairns 1988), and can then accumulate substances, such as pollutants, within their tissues. Seabirds therefore function as indicators of ecosystem health in marine environments (Cairns 1988).

Due to their wide-ranging natures, seabirds can act as vectors for the transmission of pathogens (bacteria, viruses and fungi) and parasites across both terrestrial and marine habitats (Mallory *et al.* 2010). Indeed, the life history characteristics of seabirds, such as their longevity, migratory behaviour, and affinity to densely packed breeding colonies, likely aid the transfer of infectious agents between both individuals and colonies (Schreiber & Burger 2001). For example, studies examining external parasites (i.e., ticks) in seabirds have shown evidence of trans-oceanic host dispersal of tick-borne pathogens like the zoonotic intracellular bacterium *Coxiella* sp. (Dietrich *et al.* 2011; Gómez-Díaz *et al.* 2012; Duron *et al.* 2014; McCoy *et al.* 2016). While parasites are recognised as important components of marine ecosystems (McCoy *et al.* 2016; Khan *et al.* 2019), both external (e.g., ticks and mites) and internal (e.g., cestodes, nematodes and trematodes) parasites can affect their seabird host via competition for resources (Khan *et al.* 2019). For example, tick infestations have led to increased mortality in both Black-browed Albatross *Thalassarche melanophris* and Roseate Tern *Sterna dougallii* colonies (Bergström *et al.* 1999; Ramos *et al.* 2001). Furthermore, internal parasites are common in seabirds, and both adult and juvenile birds are exposed to a variety of intestinal parasites via their food consumption (Gaspard & Schwartzbrod 2003).

In addition to parasites, a range of pathogens also infect seabirds. One example of this is 'The Tern Virus', a virus described in Common Terns *S. hirundo* in South Africa after a mass mortality event in 1961, which bears similarities to 'Newcastle Virus' (Alexander 1995). The Tern Virus belongs to the myxovirus group and was classified as Influenza A H5N3, via identification from bird carcasses

stranded on beaches in Capetown, South Africa (Rowan 1962; Becker 1963; Becker 1966). Avian Influenza A viruses are considered a global public health threat because they are zoonotic (transmission from animals to humans is possible) and can be fatal to humans (Perdue & Swayne 2005). Indeed, many viral pathogens are highly mutable, and can adapt quickly and infect a wide range of hosts (Amitai *et al.* 2020). Another influenza strain, Influenza A H5N1, originated in domestic animals and evolved to spread worldwide, infecting different hosts, including wild birds and humans (Perkins & Swayne 2002). Due to the potential wide-spread impacts of parasites and pathogens, monitoring of bird colonies is an important part of disease surveillance (Parson & Vanstreels 2016), not solely for conserving bird colonies, but also for having the potential to protect the health of livestock and humans (Brunner *et al.* 2009).

When faced with infection via parasitism and/or pathogens, seabirds have evolved a range of defence mechanisms. Initially, the innate immune system, involving maternal antibodies, protects chicks during the first weeks of life and includes phagocytic cells, complement serum proteins (which work together with antibodies to lyse target cells), and other blood proteins, all of which help to create both chemical and physical barriers (Hammouda *et al.* 2012). In addition, the adaptive immune system (B and T cells, humoral immunity) is important for defending against some specific pathogen infections and is developed through host exposure to a pathogen (Rumińska *et al.* 2008). The primary organs involved in the development of adaptive immunity in birds are the bursa of Fabricius, the thymus and bone marrow (Davison *et al.* 2008). However, other lymphoid organs, such as the spleen, the mucosa associated with lymphoid tissue, and more diffuse lymphoid tissues, are secondary sites of blood cell production that contribute to immunity (Davison 2014). Because younger birds are less likely to have prior exposure to infections, they may be more susceptible to diseases than adults (Härtle *et al.* 2013). Chicks that survive this initial period will go on to develop adaptive immunity from pathogen exposure, helping to defend themselves against future infections (Pihlaja *et al.* 2006).

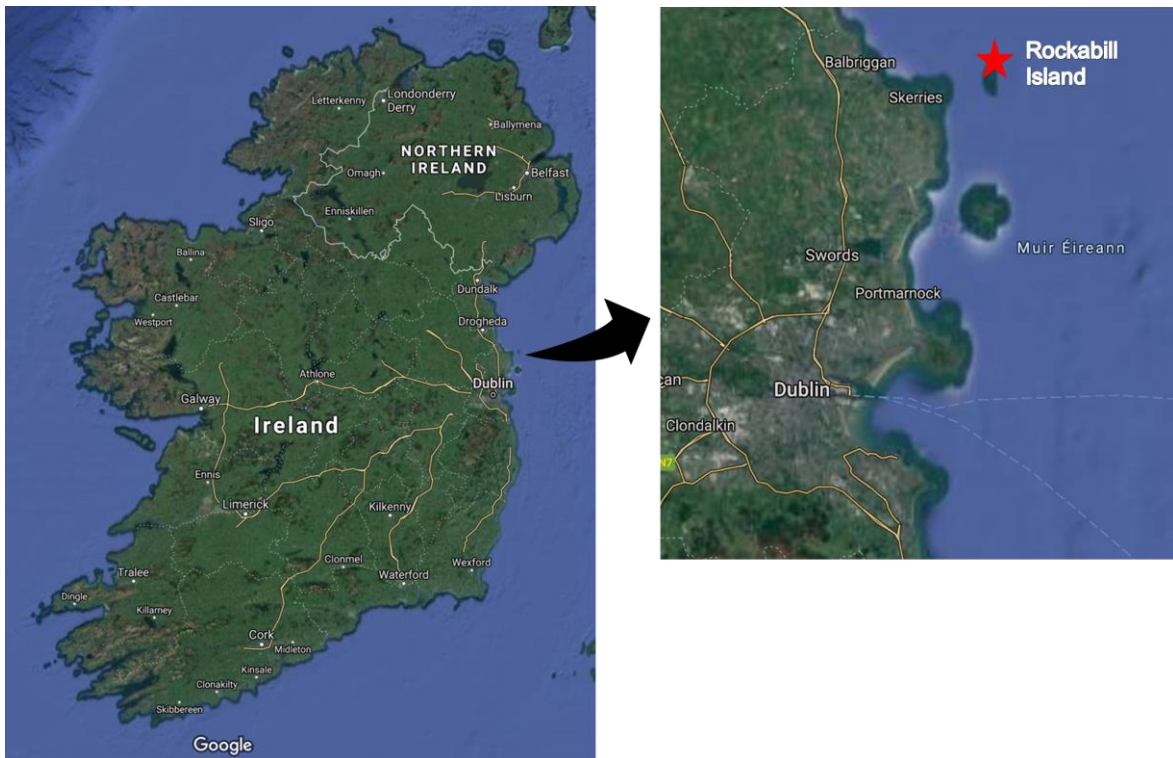Here we studied young Common, Arctic (*S. paradisaea*), and Roseate Terns from Rockabill Island, off the east coast of the Republic of Ireland (53°35'N 6°00'W). These terns inhabit Irish waters during the breeding season months of late April to September, before migrating to western and southern Africa during the post-breeding period (Seward *et al.* 2019). All three species are considered of 'Least Concern' according to the International Union for the Conservation of Nature Red List (IUCN 2018), due to the implementation of conservation efforts over recent decades (Cabot 1996; Hoffmann *et al.*

1996; Amaral *et al.* 2010). Indeed, Roseate and Common Tern populations in Britain and Ireland have increased since the 1980s and the start of species-focused conservation projects (Lloyd *et al.* 2010). However, more recently, these tern species have been ‘Amber-listed’ and are of ‘medium conservation concern’ in Ireland, according to the recent Birds of Conservation Concern in Ireland (BoCCI) review (Gilbert *et al.* 2021). Furthermore, within Britain, Roseate Terns have been assigned to the UK ‘Red List’ and are of ‘high conservation concern’ within the most recent Birds of Conservation Concern in the United Kingdom, Channel Islands and Isle of Man assessment (Stanbury *et al.* 2021). Factors likely to influence tern population trends include predation by invasive American Mink *Neovison vison*, Red Fox *Vulpes vulpes*, Herring Gull *Larus argentatus* and Common Kestrels *Falco tinnunculus*, reduced availability of important prey fish (e.g., sandeels), and trapping in their African wintering grounds (Mitchell *et al.* 2004; Sugoto *et al.* 2009). Conservation efforts are ongoing in Ireland, and Rockabill Island was recently managed as part of an EU LIFE Nature-funded Roseate Tern Project (2015 – 2022).

Here, we examined fresh carcasses of Common, Roseate and Arctic Terns that were recovered daily during the 2018 breeding season on Rockabill Island. We describe both the macroscopic findings from necropsies and the microscopic findings from histological examinations. In particular, we present a health assessment of young terns from Rockabill Island, thereby focusing on a relatively understudied life history stage.

## Methods

Tern carcasses (N = 60) were collected from Rockabill Island by BirdWatch Ireland fieldworkers during the 2018 breeding season as part of the BirdWatch Ireland/National Parks and Wildlife Service Rockabill Island Tern Project (Figure 1). The carcasses were collected and preserved in 10% seawater formalin. Necropsies were performed approximately six months after collection, and the organs were excised and placed in 70% ethanol in preparation for histological examination of tissues.



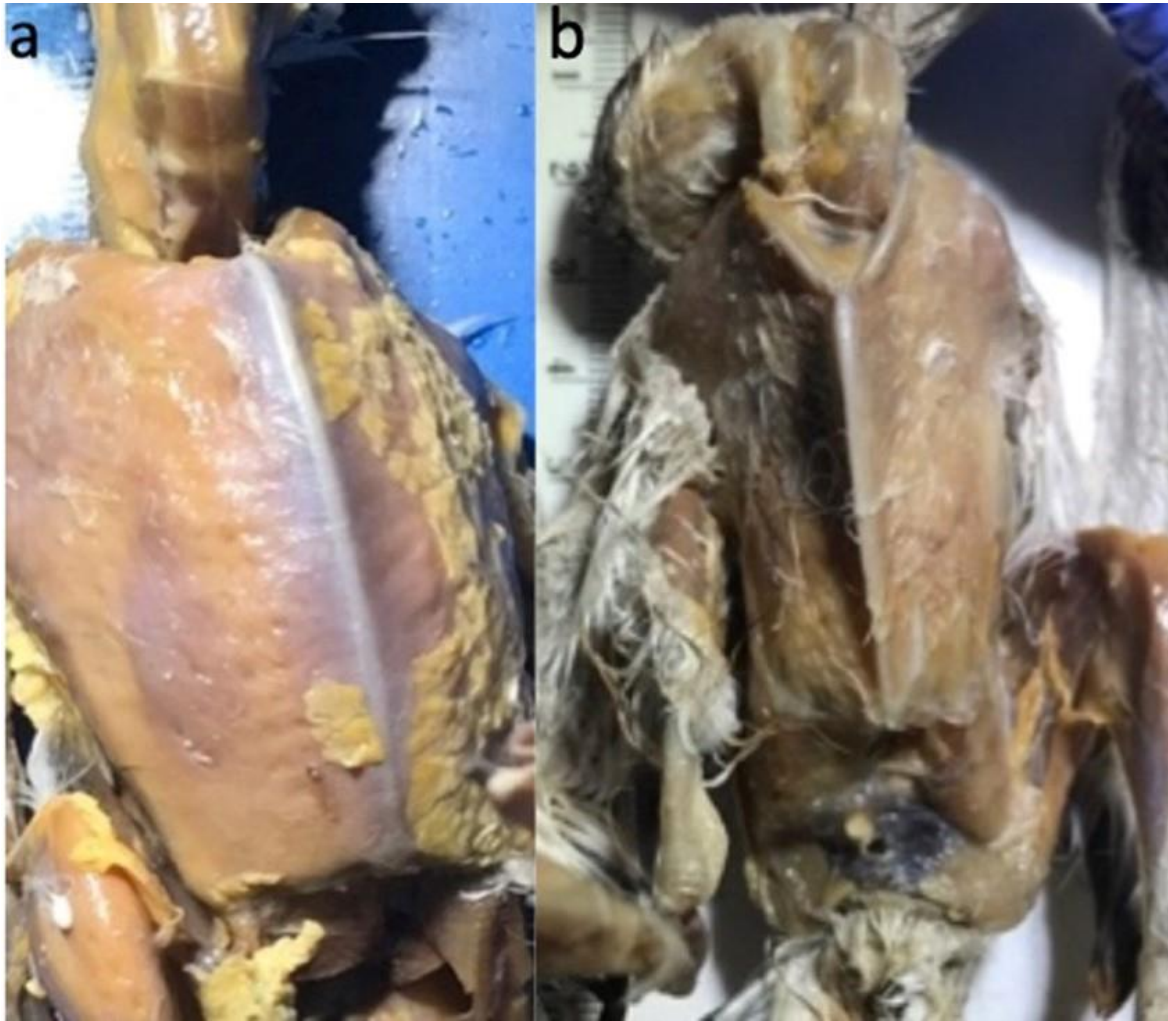
**Figure 1.** Map showing the location of Rockabill Island (where 60 tern carcasses were collected during the 2018 seabird breeding season) to the northeast of Dublin, Ireland.

*Sex, morphology and body condition*

The carcasses were sorted by species (Common, Roseate and Arctic Terns) and life stage (adults, juveniles, and chicks). Life stage was assigned according to body characteristics using methods outlined by White & Kehoe (2001) and Deschutter & Lesson (1986): 67% (N = 40) had hatchling plumage, presence of an egg tooth, and the first sheath/pin feathers, and so were considered 'chicks' (hours to 15 days old), 25% (N = 15) were considered 'juveniles' as the full body was covered with sheath/pin feathers (> 16 days old and pre-fledging), and 8% (N = 5) were adults, possessing full adult plumage without subadult characteristics and fully developed reproductive organs. Of these 60 samples, 81% (N = 49) were Common Terns, 17% (N = 10) were Roseate Terns and there was a single Arctic Tern (2%).

To obtain morphological measurements, the left tarsus and bill length of each individual were measured following Baldwin (1931). Overall body condition was classified based on the amount of muscle around the keel on the sternum and the presence of yellow fat tissue on the body (Vanezis 2001; Jones & Swayne 2004; Liu *et al.* 2005; Rae 2006; Kim *et al.* 2015). 'Good' body condition denoted the clear presence of yellow fat tissue over a plump pectoral region (Figure 2a), whilst 'poor' body condition denoted signs of pectoral tissue atrophy (Figure 2b).

During necropsies, the sex of the birds was identified where possible. Sexing was not possible for all specimens due either to their young age or brittle tissue.

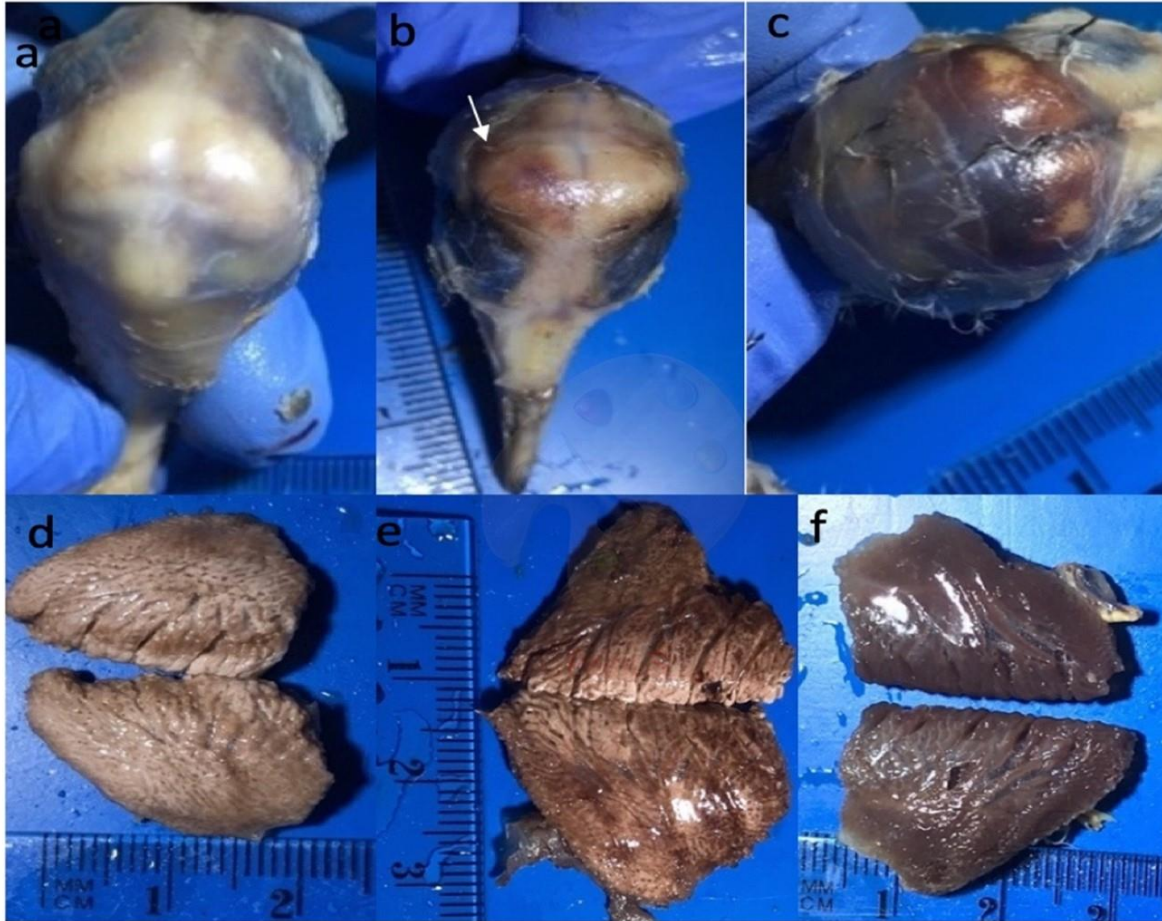

**Figure 2.** Body condition of deceased terns, collected from Rockabill Island during the 2018 breeding season, as determined during necropsies (a) ‘Good’ condition, demonstrated by the plump pectoral region and presence of yellow fat tissue; (b) ‘Poor’ condition evidenced by the atrophied pectoral region and absence of yellow fat tissue.

#### *Necropsy and gross pathology score*

Following the initial body condition assessment, a more in-depth necropsy was completed. First, each part of the body was examined to determine the gross pathology. Autolysis was taken into account and organs with areas of dull-red coloration and decaying tissue were classified as postmortem signs and were therefore not included in the reported results. Congestion in blood circulation (an accumulation of blood in the blood vessels; Vanezis 2001) was observed frequently in both the head and lungs, and a scoring system was therefore developed to determine the extent of congestion within these organs: ‘mild congestion’ was defined as small amounts of congestion/haemorrhage being

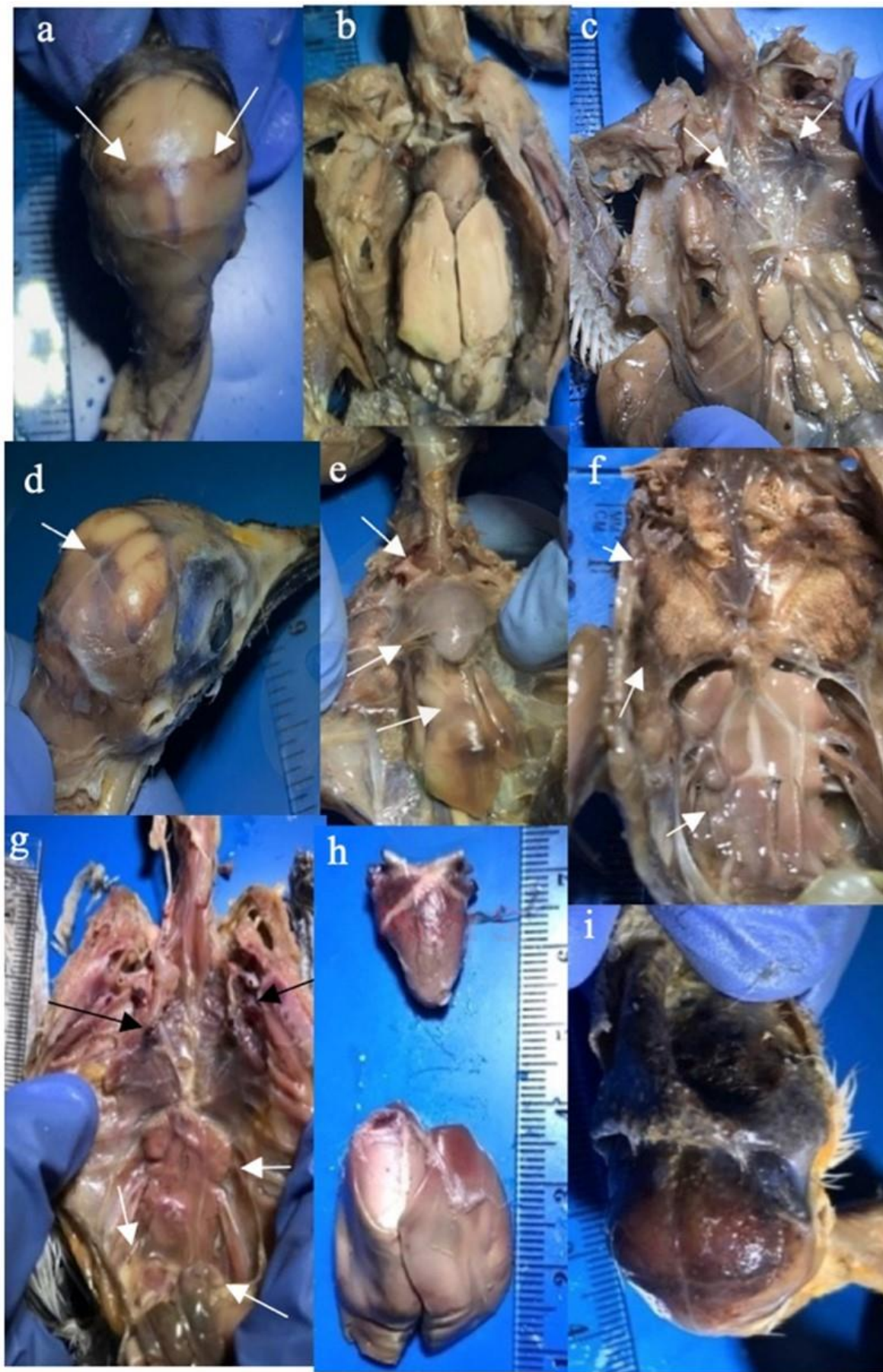present in the organ, with more than 80% of the normal organ tissue still visible (Figures 3a & d); 'moderate congestion' was indicated by a larger area of the congestion/haemorrhage, with 20–60% of the normal organ tissue still visible (Figures 3b & e); 'intense congestion' was evident when less than 20% of the normal organ tissue was visible (Figures 3c & f).



**Figure 3.** Varying levels of congestion in blood circulation in the head (a–c) and lungs (d–f) of deceased terns, collected from Rockabill Island during the 2018 breeding season; (a & d) 'Mild' congestion; (b & e) 'Moderate' congestion; (c & f) 'Intense' congestion.

To describe the overall gross pathology of each bird, as opposed to that of each organ, an additional scoring system was developed. The gross pathology score was based on findings for the whole body of each bird, including the proportion affected for each organ, as well as the number of organs affected, paying particular attention to the primary organs: the brain, heart, and lungs. For a score of 1, there was little evidence of blood circulation congestion, with 10–20% of the total organ area being

affected, and one or two of the primary organs being affected (Figures 4a–c). For example, a bird with mild congestion in the head (Figure 4a), a little enlargement of the liver (Figure 4b), no macroscopic alterations in the heart, a small focal region of congestion in the bronchi of the lungs (Figure 4c), and no substantial alterations to the rest of the body, received a score of 1. For a score of 2, the alterations were more visible and may have led to a suspected cause of death, with 20–50% of the total organ area being affected, including two or three of the three main organs (Figures 4d–f). For example, a bird showing initial signs of mild-to-moderate congestion in the skull (Figure 4d), moderate bruising of the liver (Figure 4e), moderate congestion in some of the muscle, mostly normal heart tissue, lungs with moderate congestion in places, but with the majority of the lung tissue unaffected, received a score of 2. Finally, for a score of 3, the alterations will have affected more than 50% of the total organ area, and included heavily affected brain, lungs and liver (Figure 4g–i). For example, a bird showing intense congestion in the lungs and kidneys with an abundance of fluid in the abdominal cavity (Figure 4g), intense congestion of the liver and heart (Figure 4h), intense congestion affecting 100% of the brain (Figure 4i), dilation of the heart vessels, and leg muscle with areas of haemorrhage, received a score of 3.



**Figure 4.** Photos demonstrating the overall gross pathology scoring system of deceased terns, collected from Rockabill Island during the 2018 breeding season; (a–c) Mild congestion, indicating a score of 1 for the brain, liver, and lungs respectively; (d–f) Moderate congestion, indicating a score of 2 for the brain, liver, and lungs respectively; (g–i) intense congestion, indicating a score of 3 for the lungs, liver, and brain respectively.

### *Histology*

Following the gross pathology investigation, a closer examination of the tissue pathologies was carried out using histological techniques. Tissue samples were processed manually, starting with dehydration through ascending grades of ethanol (70–100%), followed by clearing (Histo-clearâ - National Diagnostics, Atlanta, USA), before being embedded in paraffin wax (Paraplastâ, Milton Keynes, UK) and melted in an oven (Binder®, Tuttlingen, Germany). Table A1 details the steps used for the manual tissue processing (Slaoui & Fiette 2011; Grace-Jones 2012).

Once tissue was embedded in a wax block, ultrathin sections (50–70 nm thick) were cut on a Leica RM2125 microtome and transferred with forceps to a water bath set to 37–40°C. Individual tissue sections were collected on slides before being placed vertically to dry in an oven at 60°C for 20 minutes, to melt the paraffin residue. Slides were then stained using haematoxylin and eosin (Bancroft & Gamble 2012). Table A2 outlines the steps taken for the tissue staining process.

### *Statistical analyses*

Our formal statistical analyses focused on chick data, as this was the most represented life stage within our dataset. To test for differences in overall body condition and gross pathology score between chick ages, we implemented generalised linear models, accounting for Poisson distributed data, in R Version 4.0.2 (R Core Team 2020). Data from both Roseate Terns and Common Terns were combined for these analyses. All results are provided as the mean  $\pm$  standard deviation.

## Results

### *Morphology and body condition*

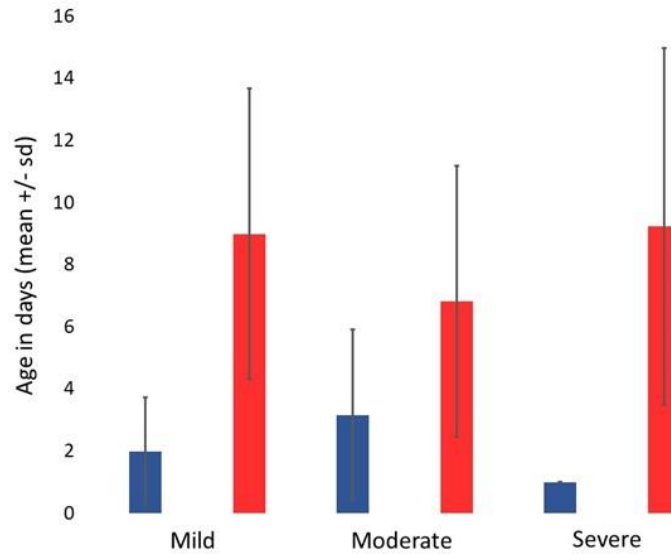
The tarsus length of adults and juveniles were similar, and both were longer than the chicks (chick  $15.92 \pm 5.23$  mm; juvenile  $20.45 \pm 4.53$  mm; adult  $21.15 \pm 0.70$  mm). There is evidence for continuous bill growth during the lifetime of the bird, with the bill length being  $12.50 \pm 10.51$  mm in chicks,  $23.01 \pm 13.88$  mm in juveniles, and  $36.90 \pm 24.39$  mm in adults.

From the 60 birds examined, 55% (N = 33) were in ‘poor’ body condition and 45% (N = 27) were in ‘good’ body condition (Table 1). There was no evidence of ‘poor’ body condition being restricted to either chicks or juveniles in the 41 birds identified as having visceral congestion in the head and lungs. In total 60% (N = 18 out of 30) of the chicks had ‘poor’ body condition, and 82% (N = 9 out of 11) of the juveniles.

**Table 1.** Proportion of adult, juvenile and chick Roseate Tern *Sterna dougallii* and Common Tern *S. hirundo* carcasses collected from Rockabill Island during the 2018 breeding season that were in either ‘good’ or ‘poor’ body condition.

	Roseate Tern			Common Tern		
	Adult	Juvenile	Chick	Adult	Juvenile	Chick
Good body condition	2	3	1	1	2	18
Poor body condition	1	2	3	1	9	17

We found a relationship between chick age and body condition ( $Z = 6.74$ ,  $P < 0.001$ ; Figure 5) with chicks found in ‘good’ body condition being older ( $8 \pm 4.6$  days) than those found in ‘poor’ condition ( $3 \pm 2.5$  days). By contrast, gross pathology did not vary with age (Figure 5; mild or moderate congestion:  $Z = -0.22$ ,  $P = 0.83$ ; mild or severe congestion:  $Z = 1.10$ ,  $P = 0.27$ ; moderate or severe congestion:  $Z = 1.52$ ,  $P = 0.13$ ).



**Figure 5.** Comparison of the gross pathology scores and body conditions (blue = ‘good’ body condition; red = ‘poor’ body condition) of tern chicks of different ages collected from Rockabill Island during the 2018 breeding season.

#### *Necropsy and gross pathology score*

Of the 60 birds, 63.3% (N = 41) had blood circulation congestion in both the lungs and head. Of these 41 birds, 65.8% (N = 27) also had ‘poor’ body condition and a gross pathology score of 2 (Table 2). In this group of 41 birds, 73% were chicks (N = 30), and 27% were juveniles (N = 11). Among the birds, 10% (N = 4) were Roseate Terns (3 chicks and 1 juvenile) and the remaining 90% (N = 37) were Common Terns (27 chicks and 10 juveniles). The birds that presented with signs of blood circulation congestion had varying degrees of body condition and gross pathology findings (Table 2).

No clear cause of death was evident for 15 of the remaining 19 birds, although two showed oral ulceration and one had pododermatitis (an inflammatory condition that affects the bottom of an animal’s foot). Ten birds had blood circulation congestion in only the head or lungs, and of these, two chicks (one Arctic Tern and one Common Tern) presented hydrocephaly, with bruising in the head and some of the body muscles. Blood congestion in only the lungs was observed in five of the chicks (four Common Tern and one Roseate Tern), two of the juveniles (Common Tern), and in one adult Roseate Tern, which also had some bruises (haematomas) in the body muscle.

**Table 2.** Summary of body condition and gross pathology findings for the 41 terns collected from Rockabill Island during the 2018 breeding season that were found to have both head and lung congestion.

	Gross pathology score	Poor body condition		Good body condition	
		Common Tern	Roseate Tern	Common Tern	Roseate Tern
Chick	1: Mild	3	0	1	0
	2: Moderate	10	2	8	2
	3: Severe	3	0	1	0
Juvenile	1: Mild	0	0	0	0
	2: Moderate	5	1	2	0
	3: Severe	3	0	0	0

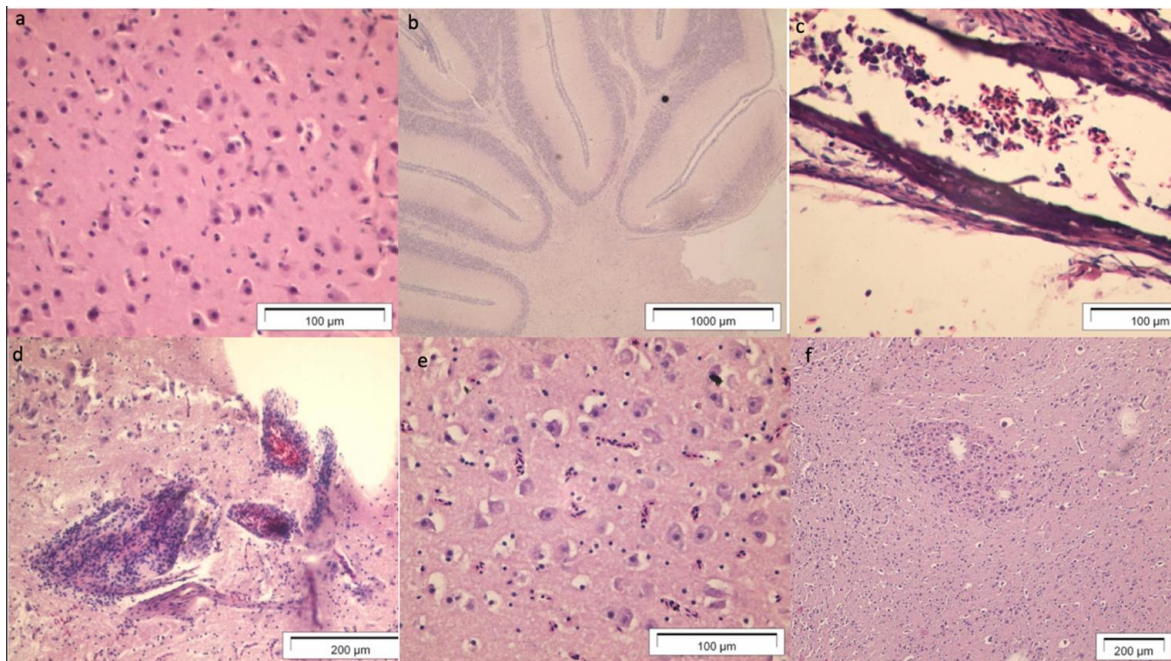
Clear causes of death were evident in four of the birds. One adult Common Tern had a cervical fracture and showed macroscopic evidence of a large blood clot in the neck and exposed bone, although otherwise it had good body condition and food in the stomach (Figure A1). A female Roseate Tern had an egg retention and congestion of abdominal tissue (Figure A1c). Two birds had gastrointestinal obstructions: one Common Tern chick had a foreign object, composed of natural material, filling its entire oesophagus, and showed signs of bloody congestion in the tissues (Figure A1b); a juvenile Common Tern was observed with fish lodged in its oesophagus, and signs of blood congestion in the stomach and surrounding tissue area (Figure A1e).

In the external examinations, other internal organs besides the lungs and the brain, were found to have other abnormalities, such as bruises, but these findings were less common than those found for visceral congestion in the head and lungs (Figure A1e – j). Many of the chicks examined still had yolk material present in the abdominal cavity and the external examinations often revealed the presence of the yolk sac scar and some general swelling of the eyes. Additional detailed descriptions of the various organs studied can be found in the Appendix.

### Histology

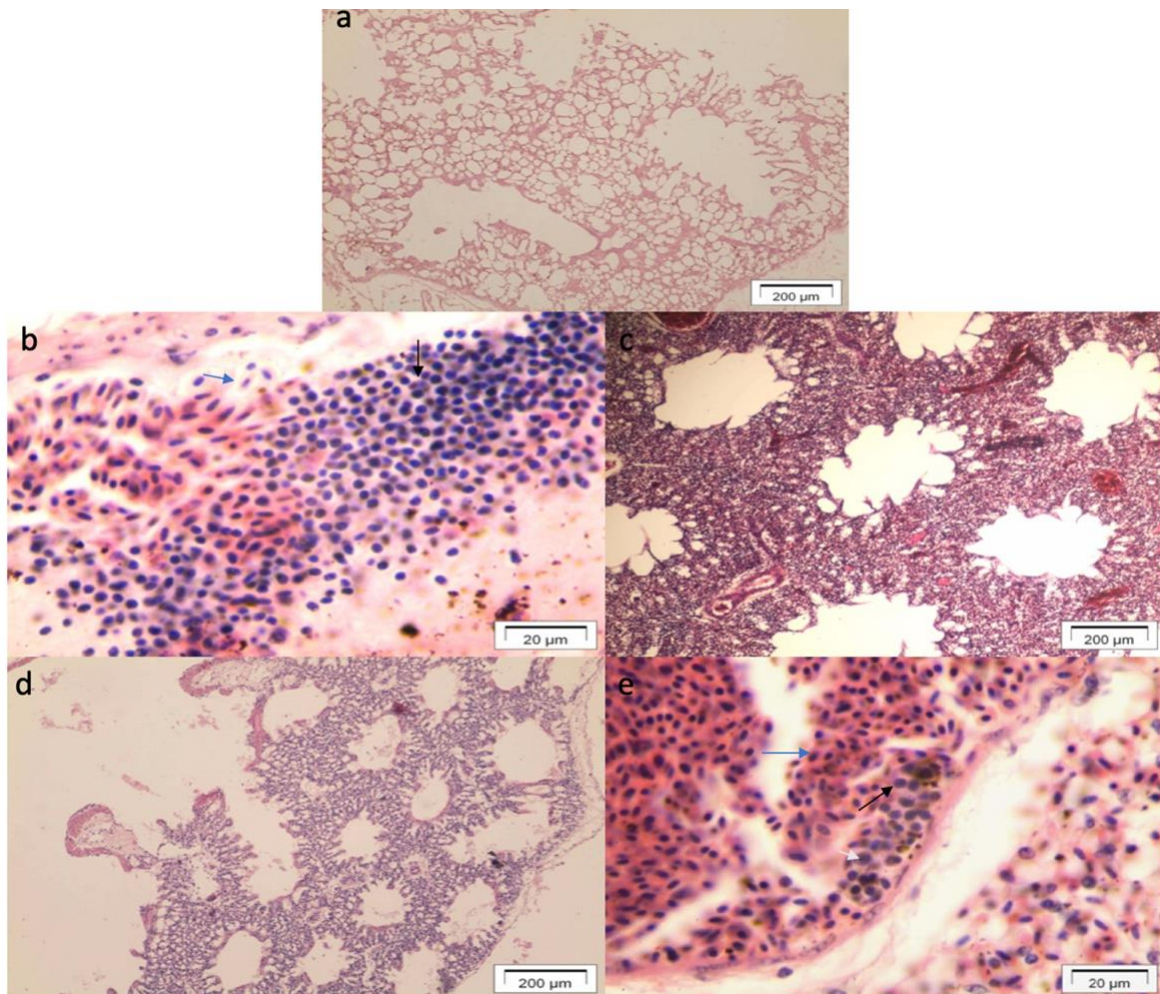
The organs examined using histology were the brain, lungs, liver, spleen, heart, kidneys, pancreas, thymus, thyroid, and intestines. Here we report the main findings for the brain and lungs. Details on findings relating to other organs can be found in the Appendix (Figure A2).

Transverse sections of the brain, showing the cerebrum and cerebellum, were prepared. In brains where blood congestion was not evident, the neurons and vessels were clearly visible as expected (Figure 7a – b). When brains were congested, there were signs of neuron degeneration, excess blood in the tissues, evidence of microglial cells (components of the central nervous system), swelling of the endothelium and perivascular space, and an infiltration of lymphocytes and macrophage infiltration in regions of the cerebrum (Figure 7d). Mild to moderate neuron degeneration was also visible (Figure 7e – f).



**Figure 7.** Histological images of the brains of deceased terns that were collected from Rockabill Island during the 2018 breeding season. (a) Normal brain tissue; (b) Normal cerebellum region; (c) Oedema in the brain tissue layers (meninges); (d) Intense presence of lymphocytic cells; (e) Neuron degeneration and oedema; (f) Focus of neuron degeneration.

Transverse sections of lung tissue were prepared. Following comparison with non-congested lung tissues (Figure 8a), congested samples showed signs of necrotic, haemorrhagic, and inflammatory lesions/infiltration. This was evidenced via the presence of blood cells including erythrocytes (Figure 8b & e), lymphocytes (Figure 8e), thrombocytes (Figure 8e) and heterophils (Figure 8b) in the interstitial area. Regions of tissue massification were visible and the alveolar space had irregularities in tissue pattern in some places (Figures 8c & d). In addition, signs of an accumulation of carbon in the alveoli of one adult bird were very clear, due to the black colouring of the tissues.



**Figure 8.** Histological images of the lungs of deceased terns that were collected from Rockabill Island during the 2018 breeding season. (a) Normal tissue; (b) Intense defence/inflammatory cell infiltration; (c) Intense presence of erythrocytic cells on the lung tissue; (d) oedema and congestion in the tissue; (e) Erythrocytic and defence cells together in the vessel and tissue. Blue arrows illustrate erythrocytes, black arrows illustrate heterophils and white arrows illustrate lymphocytes.

## **Discussion**

Reproductive success across a bird's lifetime is a result of breeding longevity (the number of seasons that an animal reproduces) and effective fecundity (the production of offspring that survive to breed; Nur 1988). Therefore, survival of young seabirds is important for securing the reproductive success of individual birds and contributing to sustainable bird populations. Based on this, ensuring the survival of young seabirds forms an important part of conservation objectives (Massias & Becker 1990). At Rockabill Island, Common and Roseate Tern numbers have been increasing since the 1990s and numbers of breeding pairs are estimated to be 1,538 for Roseate Terns (Seward *et al.* 2019) and 1,833 for Common Terns (JNCC 2021). Despite these increases in population sizes, the number of chicks fledged per pair of both species is not always high (JNCC 2021), and the factors contributing to reproductive success require more research, both at this colony and at colonies distributed elsewhere in the North Atlantic.

As chicks made up more than half of the samples examined here (N = 52), much of the discussion is devoted to the findings related to this age group.

### *Morphology and body condition*

Upon observing the external condition of the bird carcasses recovered at Rockabill Island, no obvious signs of predation were found. A lack of predation may be due to the presence of at least three wardens, who actively deter large gulls, at the colony during the tern breeding season. Evidence of parasites, both internal and external, was scarce, and necropsy observations also revealed little or no evidence of marine litter.

Examinations of the majority of the 60 tern carcasses revealed inconclusive findings regarding cause of death, with only four birds presenting clear causes of death. This being said, signs of starvation, evidenced via observations of 'poor' body condition, were present across many of the carcasses. Tern starvation may be due to factors such as climate change and extreme weather events impacting parental care and provisioning rates (Baird 1990; Dias *et al.* 2019; Piec & Dunn 2021), pollution (Dias *et al.* 2019), fluctuating food availability/food shortages (Monaghan 1992; Suddaby & Ratcliffe 1997; Piec & Dunn 2021), provision of poor quality food items (Harris *et al.* 2008; Schrimpf *et al.* 2012), and competition with commercial fisheries (Camphuysen & Garthe 2000), particularly those targeting important seabird prey items such as sandeels (Mitchell *et al.* 2020; Cook *et al.* 2014) and sprat

(Cummins *et al.* 2016). Indeed, Roseate Terns have low behavioural plasticity regarding prey items (Monaghan 1992) and may therefore be particularly susceptible to the effects of prey shortages. In addition to these factors, the recent 'Species Action Plan' for Roseate Terns also highlighted offshore windfarms as exerting possible pressures on terns through impacts on their foraging areas (Piec & Dunn 2021). It is possible that mortality of young terns at Rockabill Island is being driven by some, or all, of these pressures and more detailed studies are warranted.

Signs of malformations, like hydrocephaly (fluid accumulating in the brain), present in a small number of carcasses (N = 2), could be indicative of viral infections or chemical pollution. For instance, Marusak *et al.* (2010) reported hydrocephaly in Chickens (*Gallus gallus domesticus*) infected with parvoviruses. Furthermore, Hoffman *et al.* (1988) reported similar malformations in aquatic wild birds contaminated with high doses of selenium. Indeed, a previous study of Rockabill Island Common Tern eggs revealed higher levels of persistent pollutants in comparison to eggs from other colonies, although these pollution levels were still below established toxicological thresholds (Power *et al.* 2021). In another study, persistent organic pollutants in the tissues of Rockabill Island Common Terns were deemed to be below levels that would lead to reproductive failure, although some were higher than recommended levels (Acampora *et al.* 2017). Our findings reveal that it is possible that pathogens and pollutants are impacting tern species at Rockabill Island, and future studies are recommended to further examine pathogens and pollutants in individual birds across various life stages.

#### *Necropsy features and histological results*

Both haemorrhages and congestion in blood vessels were observed during the investigation, indicating excessive amounts of blood present in the surrounding tissue, or within the blood vessels, respectively (Vanezis 2001). Gross pathology examinations showed signs of congestion in blood vessels, mostly in the head and lungs, which is compatible with previous descriptions of the West Nile, Influenza and Gumboro Viruses in birds (Jindal *et al.* 2004; Stallknecht 2007; Kozdruń *et al.* 2015). The abdominal buildup of fluid found in some samples is a feature also described during investigations of H5N8/H5N1 infection in birds from the United Kingdom caused by heart and pulmonary failure (Julian 1993; Balog 2003; Lean *et al.* 2021). Further research is required to identify the potential presence of any such pathogens in tern species in Ireland.

Most of the carcasses examined showed signs of neuron degeneration which, according to Elkin (2019), is a characteristic of birds infected with arboviruses like Influenza A, West Nile Virus and Newcastle Disease (Alexander 2000; Hubálek 2004; Diaz *et al.* 2008; Donadieu *et al.* 2013). The inflammatory cell infiltration and tissue degeneration that we observed in many organs, are similar to previous reports of avian immune reactions (Horimoto & Kawaoka 2001; Taubenberger & Morens 2008; Koratkar *et al.* 2014) and/or cases of viral infection (Perkins & Swayne 2001; Perkins & Swayne 2002; Keawcharoen *et al.* 2008; Mohamed 2013). In addition, though Acampora *et al.* (2017) reported that the level of pollutants in Common Terns was not a concern for the tern population in Rockabill Island, the presence of inflammatory cells throughout the tissues could be a reaction to chemical toxicity (Burger & Gochfeld 2001, Abdo-El-Shamy 2012). Future studies of the exposure of these seabirds to chemical pollutants, such as via toxicological analyses of the food items they are consuming, will provide useful information. Detailed investigations of the range of factors potentially challenging the immune system of terns at Rockabill Island will provide valuable insights into the pressures faced by these seabirds and will inform future conservation efforts.

### *Conclusions*

In general, more detailed information from parent birds is needed to provide a better understanding of how the health of adult birds contributes to chick and juvenile mortality. For instance, the age of parent birds is an important factor for successful population growth, with older parents having stronger chicks with higher levels of immune defence cells (Wendeln & Becker 1999; Bouwhuis *et al.* 2015). Recent population increases at tern colonies in Ireland, accompanied by reduced fledging success, may be due to a high proportion of younger, less experienced breeding birds. Younger parent birds might be impacting chick health and survival, whilst changes in prey availability may also be impacting body condition in both adults and chicks. Increased sampling at seabird colonies is recommended and should include the collection of a wide range of sample types as outlined in Thibault *et al.* (2019) and de Matos *et al.* (2020). For instance, carcasses, cloacal swabs, mouth swabs, and the content of eggs can be used to identify harmful bacteria present in colonies (Padilla *et al.* 2006, Benskin 2009). Samples of organs, such as muscles, lungs, liver, kidneys and brain, can be used to investigate a wide range of factors, including pollution (Rutkowska *et al.* 2019), nutrition/diet information (Roman *et al.* 2020), and pathogen identification (Becker & Finck 1986). Feathers can provide important information about exposure to more persistent marine pollutants as they accumulate these substances during growth (Furness & Camphuysen 1997).

Furthermore, while examination of various tissues can provide informative data on the health of these seabirds, a broader approach is also recommended to better understand the factors contributing to mortality and to decreased reproductive success. For instance, while colonial nesting may provide defence against predators, density-dependent competition for resources, including food and nest sites, may impact survival and/or reproductive success. Previous studies have reported a negative relationship between colony size and reproductive success for a range of seabirds (Gaston *et al.* 1983; Hunt, 1986; Lewis *et al.* 2001; Tella *et al.* 2001. McKnight *et al.* 2019). In addition, reduced immune function in both Common Tern and Black-headed Gull (*Chroicocephalus ridibundus*) nestlings was recently reported for offspring at larger colonies (Minias *et al.* 2019; Kamiński *et al.* 2021). Future investigations of tern density, tern health, and reproductive success at Rockabill Island will provide important information on the potential pressures facing the birds at this colony and are necessary for comparisons to be made with other European colonies where per capita population growth rates have not been in decline.

This study is a first step towards a health assessment of the terns at Rockabill Island and ongoing data collection is encouraged to help inform the management of these iconic migratory species.

### **Acknowledgements**

The authors wish to thank BirdWatch Ireland, the Rockabill Island wardens (Luíse Ní Dhonnabháin & David Miley), and boat crew for their support in collecting samples; laboratory technicians, Mary Veldon and John Kennedy, at the Atlantic Technological University, for their support; and anonymous reviewers for their comments.

## References

- Abdo-El-Shamy, S. 2012.** Bioaccumulation of some heavy metals and histopathological, ultrastructure alternation in kidney, brain and lung of migratory birds around Manzala Lake. *Assiut Veterinary Medicine Journal* 58: 134.
- Acampora, H., White, P., Lyashevskaya, O. & O'Connor, I. 2017.** Presence of persistent organic pollutants in a breeding common tern (*Sterna hirundo*) population in Ireland. *Environmental Science and Pollution Research* 24: 13025–13035.
- Alexander, D. J. 1995.** The epidemiology and control of avian influenza and Newcastle disease. *Journal of Comparative Pathology* 112:105–126.
- Alexander, D. J. 2000.** A review of avian influenza in different bird species. *Veterinary Microbiology* 74: 3–13.
- Amaral, J. J., Almeida, S., Sequeira, M. & Neves, V. C. 2010.** Black rat *Rattus rattus* eradication by trapping allows recovery of breeding roseate tern *Sterna dougallii* and common tern *S. hirundo* populations on Feno Islet, the Azores, Portugal. *Conservation Evidence* 7: 16–20.
- Amitai, A., Sangesland, M., Lingwood, D. & Chakraborty, A. 2020.** Influenza virus geometry shapes the immune response against it. *Bulletin of the American Physical Society* 65: 1–10.
- Baird, P. H. 1990.** Influence of abiotic factors and prey distribution on diet and reproductive success of three seabird species in Alaska. *Ornis Scandinavica* 21: 224–235.
- Baldwin, S. P., Oberholser, H. C. & Worley, L. G. 1931.** *Measurements of birds*, Cleveland Museum of Natural History: 1-167. Cleveland Museum of Natural History, Ohio.
- Balog, J. M. 2003.** Ascites syndrome (pulmonary hypertension syndrome) in broiler chickens: Are we seeing the light at the end of the tunnel? *Avian and Poultry Biology Reviews* 14: 99–126.
- Bancroft, J. D. & Gamble, M. 2012.** *Theory and Practice of Histological Techniques*, 6<sup>th</sup> Edition: 1–699. Churchill Livingstone, Edinburgh.

- Becker, P. H. & Finck, P. 1986.** The meaning of nest density and nest location for the breeding success of Common Tern *Sterna hirundo* in colonies of a Wadden Sea island. *Ornithological Institute* 33: 192–207.
- Becker, W. B. 1963.** The morphology of tern virus. *Virology* 20: 318–27.
- Becker, W. B. 1966.** The isolation and classification of tern virus: influenza virus A/tern/South Africa/1961. *Journal of Hygiene* 64: 309–320.
- Benskin, C. M. H., Wilson, K., Jones, K. & Hartley, I. R. 2009.** Bacterial pathogens in wild birds: a review of the frequency and effects of infection. *Biological Reviews* 84: 349–373.
- Bergström, S., Haemig, P. D. & Olsen, B. 1999.** Increased mortality of black-browed albatross chicks at a colony heavily-infested with the tick *Ixodes uriae*. *International Journal for Parasitology* 29: 1359–1361.
- Bouwhuis, S., Vedder, O. & Becker, P. H. 2015.** Sex-specific pathways of parental age effects on offspring lifetime reproductive success in a long-lived seabird. *Evolution* 69: 1760–1771.
- Brunner, E. J., Jones, P. J., Friel, S. & Bartley, M. 2009.** Fish, human health and marine ecosystem health: policies in collision. *International Journal of Epidemiology* 38: 93–100.
- Burger, J. & Gochfeld, M. 2001.** Effects of chemicals and pollution on seabirds. In: Schreiber, E. A. & Burger, J. *Biology of Marine Birds*: 485–525. CRC Press, Florida.
- Cabot, D. 1996.** Performance of the Roseate Tern Population Breeding in North-West Europe: Ireland, Britain and France, 1960–94. *Biology and Environment: Proceedings of the Royal Irish Academy* 96B: 55–68.
- Cairns, D. K. 1988.** Seabirds as indicators of marine food supplies. *Biological Oceanography* 5: 261–271.

- Camphuysen, C. J. & Garthe, S. 2000.** Seabirds and commercial fisheries: population trends of piscivorous seabirds explained? In: Kaiser M. J. & de Groot S. J. (eds.) *The effects of fishing on non-target species and habitats: Biological, conservation and socio-economic issues*: 163–184. Blackwell, New Jersey.
- Cartraud, A. E., Le Corre, M., Turquet, J. & Tourmetz, J. 2019.** Plastic ingestion in seabirds of the western Indian Ocean. *Marine Pollution Bulletin* 140: 308–314.
- Cook, A. S. C. P., Dadam, D., Mitchell, I., Ross-Smith, V. H. & Robinson, R. A. 2014.** Indicators of seabird reproductive performance demonstrate the impact of commercial fisheries on seabird populations in the North Sea. *Ecological Indicators* 38: 1–11.
- Cummins, S., Lewis, L. J. & Egan, S. 2016.** Life on the Edge – Seabirds and Fisheries in Irish Waters. *BirdWatch Ireland Report*: pp 43.
- Davison, F. 2014.** The importance of the avian immune system and its unique features. In: Schat, K., A., Kaspers, B. & Kaiser, P. *Avian Immunology*, 2<sup>nd</sup> Edition: 1–9. Academic Press, London.
- Davison, F., Kaspers, B., & Schat, K. A. 2008.** The Avian Mucosal Immune System. In: Davison, F., Kaspers, B. & Schat, K. A. *Avian Immunology*, 1<sup>st</sup> Edition: 241–242. Academic Press, London.
- Deschutter, A. & Lesson, S. 1986.** Feather growth and development. *World's Poultry Science Journal* 42: 259–267.
- Dias, M. P., Martin, R., Pearmain, E. J., Burfield, I. J., Small, C., Phillips, R. A., Yates, O., Lascelles, B., Borboroglu, G. P. & Croxall, J. P. 2019.** Threats to seabirds: a global assessment. *Biological Conservation* 237: 525–537.
- Diaz, L. A., Komar, N., Visintin, A., Juri, M. J. D., Stein, M., Allende, R. L., Spinsanti, L., Konigheim, B., Aguilar, J., Laurito, M., Almirón, W. & Contigiani M. 2008.** West Nile virus in birds, Argentina. *Emerging Infectious Diseases* 14: 689.

- Dietrich, M., Gómez-Díaz, E. & McCoy, K. D. 2011.** Worldwide distribution and diversity of seabird ticks: implications for the ecology and epidemiology of tick-borne pathogens. *Vector-Borne and Zoonotic Diseases* 11: 453–470.
- Donadieu, E., Bahuon, C., Lowenski, S., Zientara, S., Couplier, M. & Lecollinet, S. 2013.** Differential virulence and pathogenesis of West Nile viruses. *Viruses* 5: 2856–2880.
- Dunn, P. O. 2019.** Changes in timing of breeding and reproductive success in birds. *Effects of Climate Change on Birds* 9: 113–128.
- Duron, O., Jourdain, E. & McCoy, K. D. 2014.** Diversity and global distribution of the *Coxiella* intracellular bacterium in seabird ticks. *Ticks and Tick-borne Diseases* 5: 557–563.
- Elkin, N. 2019.** Poultrymed: Atlases: Histopathology: Avian encephalomyelitis, Available from: [/www.poultrymed.com/Poultrymed/Templates/showpage.asp?DBID=1&LNGID=1&TMID=103&FID=1607](http://www.poultrymed.com/Poultrymed/Templates/showpage.asp?DBID=1&LNGID=1&TMID=103&FID=1607) [accessed April 2022].
- Forster, P. 2014.** Ten years on: Generating innovative responses to avian influenza. *Ecohealth* 11: 15–21.
- Furness, R. W. & Camphuysen, K., 1997.** Seabirds as monitors of the marine environment. *ICES Journal of Marine Science* 54: 726–737.
- Gaspard, P. G. & Schwartzbrod, J. 2003.** Parasite contamination (helminth eggs) in sludge treatment plants: definition of a sampling strategy. *International Journal of Hygiene and Environmental Health*, 206: 117–122.
- Gaston, A. J., Chapdelaine, G. & Noble, D. G. 1983.** The growth of Thick-billed Murre chicks at colonies in Hudson Strait: inter-and intra-colony variation. *Canadian Journal of Zoology* 61: 2465–2475.
- Gilbert, G., Stanbury, A. & Lewis, L. 2021.** Birds of conservation concern in Ireland 4: 2020–2026. *Irish Birds* 43: 1–22.

- Gómez-Díaz, E., Morris-Pocock, J. A., González-Solís, J. & McCoy, K. D. 2012.** Trans-oceanic host dispersal explains high seabird tick diversity on Cape Verde islands. *Biology Letters* 8: 616–619.
- Grace-Jones, W. 2012.** Tissue Microarray. In: Bancroft, D. & Gamble, M. (eds.) *Theory and Practice of Histological Techniques*, 6<sup>th</sup> Edition: 527–535. Churchill Livingstone, Edinburgh.
- Hammouda, A., Selmi, S., Pearce-Duvel, J., Chokri, M. A., Arnal, A., Gauthier-Clerc, M. & Boulinier, T. 2012.** Maternal Antibody Transmission in Relation to Mother Fluctuating Asymmetry in a Long-Lived Colonial Seabird: The Yellow-Legged Gull *Larus michahellis*. *PLOS ONE* 7: e34966.
- Harris, M. P., Newell, M., Daunt, F., Speakman, J. R. & Wanless, S. 2008.** Snake Pipefish *Entelurus aequoreus* are poor food for seabirds. *Ibis* 150: 413–415.
- Härtle S., Magor K. E., Göbel, T. W., Davison, F. & Kaspers, B. 2013.** Structure And Evolution of Avian Immunoglobulins. In: Schat K. A., Kaspers B. & Kaiser P. *Avian Immunology*, 2<sup>nd</sup> Edition: 103–120. Academic Press, London.
- Hoffman, D. J., Ohlendorf, H. M. & Aldrich, T. W. 1988.** Selenium teratogenesis in natural populations of aquatic birds in central California. *Archives of Environmental Contamination and Toxicology* 17: 519–525.
- Hoffmann, L., Hafner, H. & Salathé, T. 1996.** The contribution of colonial waterbird research to wetland conservation in the Mediterranean region. *Colonial Waterbirds* 19: 12–30.
- Horimoto, T. & Kawaoka, Y. 2001.** Pandemic threat posed by avian influenza A virus. *Clinical Microbiology Reviews* 14: 129–149.
- Hubálek, Z. 2004.** An annotated checklist of pathogenic microorganisms associated with migratory birds. *Journal of Wildlife Diseases* 40: 639–659.
- Hunt Jr, G. L., Eppley, Z. A. & Schneider, D. C. 1986.** Reproductive performance of seabirds: the importance of population and colony size. *The Auk* 103: 306–317.

- IUCN (International Union for Conservation of Nature) 2018.** The IUCN Red List of the Threatened Species. Version 2018–2019 (online). Available from [www.iucnredlist.org](http://www.iucnredlist.org) [accessed January 2019].
- Jindal, N., Mahajan, N. K., Mittal, D., Gupta, S. L. & Khokhar, R. S. 2004.** Some epidemiological studies on infectious bursal disease in broiler chickens in parts of Haryana, India. *International Journal of Poultry Science* 3: 478–482.
- JNCC (Joint Nature Conservation Committee) 2021.** *Common tern (Sterna hirundo)* (online). Available from <https://jncc.gov.uk/our-work/common-tern-sterne-hirundo/> [accessed April 2022].
- Jones, Y. L. & Swayne, D. E. 2004.** Comparative pathobiology of low and high pathogenicity H7N3 Chilean avian influenza viruses in chickens. *Avian Diseases* 48: 119–128.
- Julian, R. J. 1993.** Ascites in poultry. *Avian Pathology* 22: 419–454.
- Kamiński, M., Janiszewski, T., Indykiewicz, P., Nowakowski, J. J., Kowalski, J., Dulisz, B. & Minias, P. 2021.** Density-dependence of nestling immune function and physiological condition in semi-precocial colonial bird: a cross-fostering experiment. *Frontiers in Zoology* 18: 7.
- Keawcharoen, J., Van Riel, D., Van Amerongen, G., Bestebroer, T., Beyer, W. E., Van Lavieren, R., Osterhaus, A. D. M. E., Fouchier, R. A. M. & Kuiken, T. 2008.** Wild ducks as long-distance vectors of highly pathogenic avian influenza virus (H5N1). *Emerging Infectious Diseases* 14: 600.
- Khan, J. S., Provencher, J. F., Forbes, M. R., Mallory, M. L., Lebarbenchon, C. & McCoy, K. D. 2019.** Parasites of seabirds: A survey of effects and ecological implications. *Advances in Marine Biology* 82: 1–50.
- Kim, H. R., Kwon, Y. K., Jang, I., Lee, Y. J., Kang, H. M., Lee, E. K. & Lee, H. K. 2015.** Pathologic changes in wild birds infected with highly pathogenic avian influenza A (H5N8) viruses, South Korea, 2014. *Emerging Infectious Diseases* 21: 775.

- Koratkar, S. S., Pawar, S. D., Shelke, V. N., Kale, S. D. & Mishra, A. C. 2014.** Pathogenicity of avian influenza H11N1 virus isolated from wild aquatic bird Eurasian Spoonbill (*Platalea leucorodia*). *The Indian Journal of Medical Research* 139: 782.
- Kozdruń W., Czekaj H. & Styś N. 2015.** Avian zoonoses – a review. *Bulletin of the Veterinary Institute in Pulawy* 59: 171–178.
- Lean, F. Z., Núñez, A., Banyard, A. C., Reid, S. M., Brown, I. H. & Hansen, R. D. 2021.** Gross pathology associated with highly pathogenic avian influenza H5N8 and H5N1 in naturally infected birds in the UK (2020–2021). *Veterinary Record* 190: e731.
- Lewis, S., Sherratt, T. N., Hamer, K. C. & Wanless, S. 2001.** Evidence of intra-specific competition for food in a pelagic seabird. *Nature* 412: 816–819.
- Liu, J., Xiao, H., Lei, F., Zhu, Q., Qin, K., Zhang, X. W., Zhang, L. X., Zhao, D., Whang, G., Feng, Y., Ma, J., Liu, W., Wang, J. & Gao, F. 2005.** Highly pathogenic H5N1 influenza virus infection in migratory birds. *Science* 309: 1206–1206.
- Lloyd, C., Tasker, M. L. & Partridge, K. (eds.) 2010.** *The Status of Seabirds in Britain and Ireland*. Poyser, London.
- Mallory, M. L., Robinson, S. A., Hebert, C. E. & Forbes, M. R. 2010.** Seabirds as indicators of aquatic ecosystem conditions: a case for gathering multiple proxies of seabird health. *Marine Pollution Bulletin* 60: 7–12.
- de Matos, A. M. R. N., Domit, C. & Bracarense, A. P. F. R. L. 2020.** Seabirds: studies with parasitofauna and potential indicator for environmental anthropogenic impacts. *Semina: Ciências Agrárias* 41: 1439–1450.
- Marusak, R. A., Guy, J. S., Abdul-Azis, T. A., West, M. A., Fletcher, O. J., Day, J. M., Zsak, L. & Barner, J. H. 2010.** Parvovirus-associated cerebellar hypoplasia and hydrocephalus in day old broiler chickens, *Avian Diseases* 54: 156–160.

- Massias A. & Becker P. H. 1990.** Nutritive value of food and growth in Common Tern *Sterna hirundo* chicks. *Ornis Scandinavica* 21: 187–194
- McCoy, K. D., Dietrich, M., Jaeger, A., Wilkinson, D. A., Bastien, M., Lagadec, E., Boulinier, T., Pascalis, H., Tortosa, P., Le Corre, M., Dellagi, K. & Lebarbenchon, C. 2016.** The role of seabirds of the Iles Eparses as reservoirs and disseminators of parasites and pathogens. *Acta Oecologica* 72: 98–109.
- McKnight, A., Blomberg, E. J., Irons, D. B., Loftin, C. S. & McKinney, S. T. 2019.** Survival and recruitment dynamics of Black-legged Kittiwakes *Rissa tridactyla* at an Alaskan colony. *Marine Ornithology* 47: 209–222.
- Minias, P., Gach, K., Włodarczyk, R. & Janiszewski, T. 2019.** Colony size affects nestling immune function: a cross-fostering experiment in a colonial waterbird. *Oecologia* 190: 333–341.
- Mitchell, I. Daunt, F., Frederiksen, M. & Wade, K. 2020.** Impacts of climate change on seabirds, relevant to the coastal and marine environment around the UK. *MCCIP Science Review 2020*: 382-399.
- Mitchell, P. I., Newton, S. F., Ratcliffe, N. & Dunn, T. E. (eds.) 2004.** *Seabird populations of Britain and Ireland: Results of the Seabird 2000 census (1998–2002)*. Poyser, London.
- Mohamed, M. H. 2013.** *Pathology of Poultry Diseases, lesions of avian diseases* (online). Available from [issuu.com/mohamedelariny/docs/poultry\\_diseases2](https://issuu.com/mohamedelariny/docs/poultry_diseases2) [accessed April 2022].
- Monaghan, P. 1992.** Seabirds and sandeels: the conflict between exploitation and conservation in the northern North Sea. *Biodiversity & Conservation* 1: 98–111.
- Nur, N. 1988.** The cost of reproduction in birds: an examination of the evidence. *Ardea* 55: 155–168.
- Pacyna, A. D., Jakubas, D., Ausems, A. N., Frankowski, M., Polkowska, Ż. & Wojczulanis-Jakubas, K. 2019.** Storm petrels as indicators of pelagic seabird exposure to chemical elements in the Antarctic marine ecosystem. *Science of the Total Environment* 692: 382–392.

- Padilla L. R., Whiteman, N. K., Merkel, J., Huyvaert, K. & Parker P. G. 2006.** Health assessment of seabirds on Isla Genovesa, Galápagos Islands. *Ornithological Monographs* 6: 86–97.
- Parson, N. J. & Vanstreels, R. E. T. V. 2016.** Southern African Seabird Colony Diseases Risk assessment: 1–53. Southern African Foundation for the Conservation of Coastal Birds, Cape Town.
- Perdue, M. L. & Swayne, D. E. 2005.** Public health risk from avian influenza viruses. *Avian Diseases* 49: 317–327.
- Perkins, L. E. L. & Swayne, D. E. 2002.** Susceptibility of laughing gulls (*Larus atricilla*) to H5N1 and H5N3 highly pathogenic avian influenza viruses. *Avian Diseases* 46: 877–885.
- Perkins, L. E. & Swayne, D. E. 2001.** Pathobiology of A/chicken/Hong Kong/220/97 (H5N1) avian influenza virus in seven gallinaceous species. *Veterinary Pathology* 38: 149–164.
- Piec, D. & Dunn, E. K. 2021.** International (East Atlantic) Species Action Plan for the Conservation of the Roseate Tern *Sterna dougallii* (2021–2030): 1–60. European Commission 2021.
- Pihlaja, M., Siitari, H. & Alatalo, R. V. 2006.** Maternal antibodies in a wild altricial bird: effects on offspring immunity, growth and survival. *Journal of Animal Ecology* 75: 1154–1164.
- Power, A., White, P., McHugh, B., Berrow, S., Schlingermann, M., McKeown, A., Cabot, D., Tannian, M., Newton, S., McGovern, E., Murphy, S., Crowley, D., O’Hea, L., Boyle, B. & O’Connor, I. 2021.** Persistent pollutants in fresh and abandoned eggs of Common Tern (*Sterna hirundo*) and Arctic Tern (*Sterna paradisaea*) in Ireland. *Marine Pollution Bulletin* 168: 112400.
- R Core Team 2020.** R: A language and environment for statistical computing. R Foundation for Statistical Computing, Vienna, Austria. [www.R-project.org](http://www.R-project.org).
- Rae, M. A. 2006.** The diagnostic value of necropsy. In: Harrison, G. J. & Lightfoot, T. L. (eds.). *Clinical Avian Medicine*, 2<sup>nd</sup> Edition: 661–678. Spix Publishing, Florida

- Ramos, J. A., Bowler, J., Davis, L., Venis, S., Quinn, J. & Middleton, C. 2001. Activity patterns and effect of ticks on growth and survival of tropical Roseate Tern nestlings. *The Auk* 118: 709–716.
- Reynolds, D. L. 1998. *Method to Provide Artificial Passive Immunity in Birds*, Iowa State University Research Foundation, Inc., Ames, Iowa, U.S. Patent and Trademark Office, Patent number 5,807,551.
- Roman, L., Kastury, F., Petit, S., Aleman, R., Wilcox, C., Hardesty, B. D. & Hindell, M. A. 2020. Plastic, nutrition and pollution; relationships between ingested plastic and metal concentrations in the livers of two *Pachyptila* seabirds. *Scientific Reports* 10: 1–14.
- Rowan, M. K. 1962. Mass mortality among European Common terns in South Africa in April–May 1961. *British Birds* 55: 103–114.
- Rumińska, E., Koncicki, A. & Stenzel, T. 2008. Structure and function of the avian immune system in birds. *Medycyna Weterynaryjna* 64: 265-268.
- Rutkowska, M., Bajger-Nowak, G., Kowalewska, D., Bzoma, S., Kalisińska, E., Namieśnik, J. & Konieczka, P. 2019. Methylmercury and total mercury content in soft tissues of two bird species wintering in the Baltic Sea near Gdansk, Poland. *Chemosphere* 219: 140–147.
- Schreiber, E. A. & Burger, J. 2001. Seabirds In the Marine Environment. In: Schreiber, E. A. & Burger, J. (eds.), *Biology of Marine Birds*, 1–15. CRC Press, Florida.
- Schrimpf, M. B., Parrish, J. K. & Pearson, S. F. 2012. Trade-offs in prey quality and quantity revealed through the behavioral compensation of breeding seabirds. *Marine Ecology Progress Series* 460: 247–259.
- Seward, A., Ratcliffe, N., Newton, S., Caldow, R., Piec, D., Morrison, P., Cadwallender, T, Davies, W., & Bolton, M. 2019. Metapopulation dynamics of roseate terns: Sources, sinks and implications for conservation management decisions. *Journal of Animal Ecology* 88: 138–153.

- Slaoui, M. & Fiette, L. 2011.** Histopathology procedures: from tissue sampling to histopathological evaluation. In: Gautier, J. -C. (eds) *Drug Safety Evaluation: Methods and Protocols*: 69–82. Humana Press, New York.
- Stallknecht, D. E., Nagy, E., Hunter, D. B. & Slemons, R. D. 2007.** In Avian influenza. In: Thomas, N. J., Hunter, D. B. & Atkinson, C. T. (eds.) *Infectious diseases of wild birds*: 108–130. Blackwell Press, Oxford.
- Stanbury, A., Eaton, M., Aebischer, N., Balmer, D., Brown, A., Douse, A., Lindley, P., McCulloch, N., Noble, D. & Win, I. 2021.** The status of our bird populations: the fifth Birds of Conservation Concern in the United Kingdom, Channel Islands and Isle of Man and second IUCN Red List assessment of extinction risk for Great Britain. *British Birds* 114: 723–747.
- Suddaby, D. & Ratcliffe, N. 1997.** The effects of fluctuating food availability on breeding Arctic Terns (*Sterna paradisaea*). *The Auk* 114: 524–530.
- Sugoto, R., Reid, N. & McDonald, R. A., 2009.** A Review of Mink Predation and Control for Ireland. *Irish Wildlife Manuals* 40: 1–61.
- Taubenberger, J. K. & Morens, D. M. 2008.** The pathology of influenza virus infections. *Annual Review of Pathology: Mechanisms of Disease* 3: 499–522.
- Tella, J. L., Forero, M. G., Bertellotti, M., Donázar, J. A., Blanco, G. & Ceballos, O. 2001.** Offspring body condition and immunocompetence are negatively affected by high breeding densities in a colonial seabird: a multiscale approach. *Proceedings of the Royal Society of London. Series B: Biological Sciences* 268: 1455–1461.
- Thibault, M., Houlbreque, F., Lorrain, A. & Vidal, E. 2019.** Seabirds: Sentinels beyond the oceans. *Science* 366: 813.
- Vanezis, P. 2001.** Interpreting bruises at necropsy. *Journal of Clinical Pathology* 54: 348–355.

**Wendeln, H. & Becker, P. H. 1999.** Effects of parental quality and effort on the reproduction of Common terns. *Journal of Animal Ecology* 68: 205–214.

**White, S. J. & Kehoe, C. V. 2001.** Difficulties in determining the age of Common Terns in the field. *British Birds* 94: 268–277.

**Appendix**

**Table A1.** Protocol used for the manual tissue processing that allowed closer examination of deceased tern tissue pathologies.

Substance	Time taken (hours:minutes)	Temperature (°C)
90% ethanol	00:40	26
100% ethanol	01:00	26
100% ethanol	01:00	26
100% ethanol	01:00	26
Histoclear ®	00:40	26
Histoclear ®	00:40	26
Histoclear ®	00:40	26
Paraplast ®	01:15	60
Paraplast ®	01:15	60
Paraplast ®	01:00	60

**Table A2.** Protocol used for the tissue staining process that allowed closer examination of deceased tern tissue pathologies.

Substance	Time taken (minutes:seconds)
Histoclear ®	04:00
Histoclear ®	04:00
Histoclear ®	04:00
Histoclear ®	04:00
100% ethanol	01:00
100% ethanol	00:30
95% ethanol	00:30
70% ethanol	00:30
Distilled water	01:00
Harris hematoxylin	15:00
Running tap water	03:00
0.5% acid alcohol	Three dips
Running tap water	03:00
70% ethanol	00:20
Eosin Y	02:00
95% ethanol	00:20
100% ethanol	0:20
100% ethanol	00:20
Histoclear ®	02:00
Histoclear ®	02:00

*Extra gross necropsy findings*

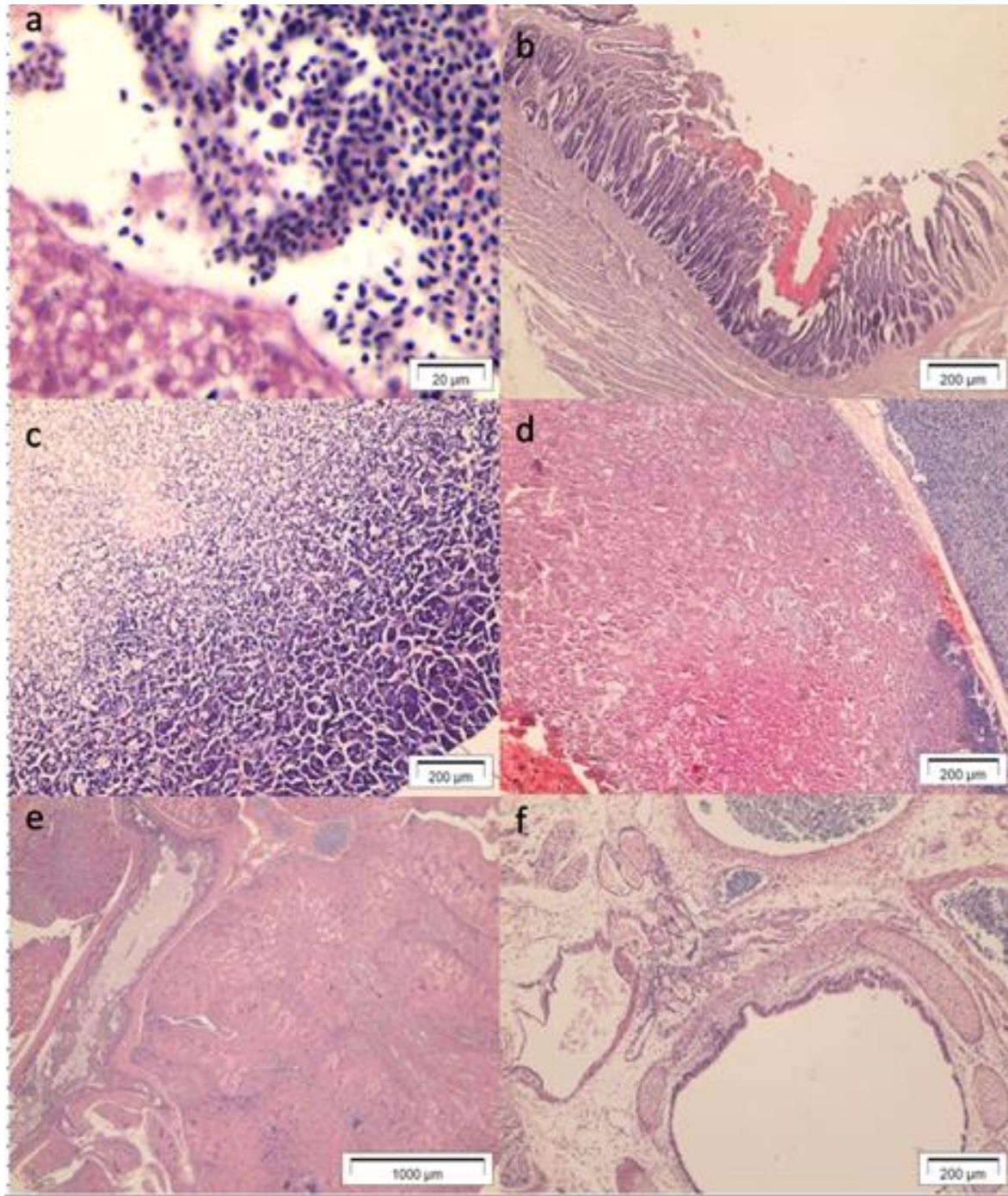
The liver and the heart of one adult Roseate Tern and one Common Tern chick presented signs of enlargement. There was no colour change in the liver and the pericardium that enclosed the heart was mildly opaque (as opposed to transparent, as it would be in normal tissue). In some cases, mild petechial signs (spots) in the pericardium were noted (Figure A1g). Also, the gall bladder and stomach were empty concomitant, there was low intestinal content and poor corporal condition, indicating that the birds had not eat for a while. One bird (a juvenile Common Tern) presented a focal bruise (haematoma) from the belly reaching the liver, indicating that it had leaned in ventral position for a long time. The stomachs of four birds had biliary imbibition in the mucosa (green colour) and hypostatic signs in the liver (poll deposition of the blood by gravity). Kidneys presented vessel dilatation and focal congestion in a few cases (N = 5). There were signs of scavenging by insects' larvae in the eyes, ears, and lateral region of the abdomen in some birds (N = 4), which started with the autolysis process in the tissue. Some affected juveniles (N = 2) showed the presence of mild tissue proliferation in the bill around the airways open (Figure A1e) and a featherless head scalp. The juveniles were undergoing feather moult, with the protective feather sheath visible. Only one of the juveniles presented pododermatitis (an inflammatory condition affecting the bottom of the animal's foot) (Figure A1i), but together with three other birds, they presented signs of featherless regions in the body and mouth ulcers (Figure A1h) surrounded by mild caseous material and mild ascites fluid in the abdominal cavity.



**Figure A1.** Other findings of macroscopic exams of deceased terns collected from Rockabill Island during the 2018 breeding season. (a) Bird showing broken neck; (b) Evidence of natural foreign object in gastrointestinal organ; (c) Evidence of egg retention; (d) Figure showing the passage blocked with fish and congestion of the surrounding tissue; (e) Tissue proliferation in the bill; (f) Sign of hydrocephaly; (g) Signs of liver mild enlargement and little bruise in the pericardium; (h) Mouth ulcers with yellowish material; (i) Signs of pododermatitis; (j) Evidence of unabsorbed yolk in chick.

*Extra histological findings*

In the muscles, the haematoma slides showed focal disarray of the tissue and inflammatory and defence cells infiltration. The liver of some birds presented regions of tissue degeneration, cellular debris, excess blood, inflammation, and hepatocellular degeneration showing tissue deformities. The pancreas appeared with foci of pancreatitis (Figure A2c), necrosis and fibrosis in some situations. The kidneys also showed signs of tubulo-interstitial nephritis, severe mononuclear infiltration with necrosis of tubular epithelium and cast (Figure A2e). The intestines showed regions of exfoliation, necrosis and lyse in the mucosal epithelium in some birds (Figure A2b) The thymus and the thyroid also presented foci of tissue necrosis and mononuclear infiltration. (Figure A2d). Ascites fluid showed presence of mononuclear cells as well. In the bronchus region, the cilia showed areas of exfoliation and tissue proliferation with disarray of the tissue (Figure A2f).



**Figure A2.** Histological findings in other organs of deceased terns collected from Rockabill Island during the 2018 breeding season. (a) Defence cells infiltration in liver tissue; (b) Intestinal region with necrosis of the mucosa; (c) Pancreas with cell disarray; (c) Thyroid with cell disarray; (c) Kidney tissue with necrosis; (f) bronchus region with alterations in the cilia and tissue.